

**Medical University of South Carolina
Charleston, SC**

**Modified Barium Swallow Study
Fluoroscopic Evaluation of Swallowing Function CPT Code 92611**

Evaluation Year: 2016

Evaluating Clinician: Humphries, Kate

Patient ID: 071F1DF8-D087

Study Number: 1

Patient Name:

Age: 58

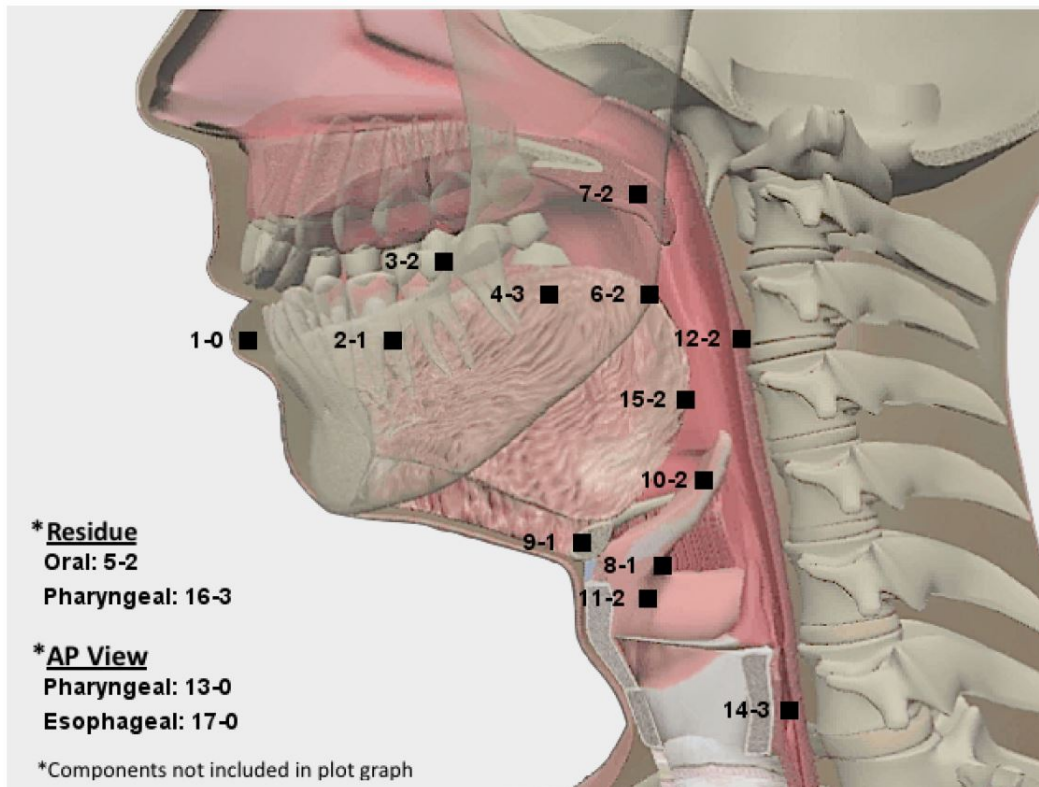
Gender: Male

MEDICAL HISTORY:

Primary (admitting) Diagnosis:

Cerebrovascular Accident

MBSImP ID: 071F1DF8-D087



MBSImP Overall Impression: Lip closure for intraoral bolus containment resulted in no labial escape. Tongue control during bolus hold allowed bolus escape to the lateral buccal cavity/floor of mouth. Bolus preparation and mastication demonstrated disorganized chewing/mashing with solid pieces of the bolus unchewed. Bolus transport/lingual motion was with repetitive/disorganized motion of the tongue. Oral residue was a collection on oral structures. Initiation of the pharyngeal swallow occurred as the bolus head was at the posterior laryngeal surface of the epiglottis. Soft palate elevation allowed bolus escape to the nasopharynx. Laryngeal elevation was decreased, with partial superior movement of the thyroid cartilage/partial approximation of the arytenoids to the epiglottic petiole. Anterior hyoid excursion demonstrated partial anterior movement. Epiglottic movement resulted in no inversion. Laryngeal vestibular closure was absent, resulting in a wide column of air/contrast within the laryngeal vestibule at the height of the swallow. Pharyngeal stripping wave was absent. Pharyngeal contraction was complete. Pharyngoesophageal segment opening yielded no distension, resulting in total obstruction of flow. Tongue base retraction allowed a narrow column of contrast or air between the retracted tongue base and the posterior pharyngeal wall. Pharyngeal residue was the majority of contrast within or on pharyngeal structures. Esophageal clearance in the upright position was complete, with only a coating of contrast, if any.

COMPONENT Number and Descriptor		Scale	CURRENT Score and Descriptor
1	Lip Closure	(0-4)	0 Resulted in no labial escape.
2	Tongue Control/Bolus Hold	(0-3)	1 Allowed bolus escape to the lateral buccal cavity/floor of mouth.
3	Bolus Prep/Mastication	(0-3)	2 Demonstrated disorganized chewing/mashing with solid pieces of the bolus unchewed.
4	Bolus Transport/Lingual Motion	(0-4)	3 Was with repetitive/disorganized motion of the tongue.
5	Oral Residue	(0-4)	2 Was a collection on oral structures.
6	Initiation of Pharyngeal Swallow	(0-4)	2 Occurred as the bolus head was at the posterior laryngeal surface of the epiglottis.
7	Soft Palate Elevation	(0-4)	2 Allowed bolus escape to the nasopharynx.
8	Laryngeal Elevation	(0-3)	1 Was decreased, with partial superior movement of the thyroid cartilage/partial approximation of the arytenoids to the epiglottic petiole.
9	Anterior Hyoid Excursion	(0-2)	1 Demonstrated partial anterior movement.
10	Epiglottic Movement	(0-2)	2 Resulted in no inversion.
11	Laryngeal Vestibular Closure	(0-2)	2 Was absent, resulting in a wide column of air/contrast within the laryngeal vestibule at the height of the swallow.
12	Pharyngeal Stripping Wave	(0-2)	2 Was absent.
13	Pharyngeal Contraction	(0-3)	0 Was complete.
14	Pharyngoesophageal Segment Opening	(0-3)	3 Yielded no distension, resulting in total obstruction of flow.
15	Tongue Base Retraction	(0-4)	2 Allowed a narrow column of contrast or air between the retracted tongue base and the posterior pharyngeal wall.
16	Pharyngeal Residue	(0-4)	3 Was the majority of contrast within or on pharyngeal structures.
17	Esophageal Clearance (upright)	(0-4)	0 Was complete, with only a coating of contrast, if any.

Oral Impairment Score: 10
Pharyngeal Impairment Score: 18
Esophageal Impairment Score: 0

Notes: